

JOURNAL OF TAZEEZ FOR PUBLIC HEALTH

AN OFFICIAL JOURNAL OF SAUDI HEALTH PROMOTION AND EDUCATION ASSOCIATION

Systematic review

Advances in Minimally invasive oculoplastic surgery: Current Techniques and Outcomes: a systematic review

Ahmed Abou El Fotouh¹, Meshal Abdulrahman Ogran², Ziyad Mohammed Alkhamash³, Abdulrahman Nasser Alqahtani⁴, Faisal Nasser M. Alahmari⁵

1. Ophthalmology Consultant, Armed Forces Hospitals Southern Region (AFHSR), Saudi Arabia
2. Senior Registrar, Ophthalmology, Aseer Central Hospital, Abha, Saudi Arabia
3. Ophthalmology Resident, Ophthalmology Department, Aseer Central Hospital, Abha, Saudi Arabia
4. Ophthalmology Resident, Ophthalmology Department, Armed Forces Hospital Southern Region, Khamis Mushait, Saudi Arabia
5. General Practitioner, Aseer Central Hospital, Abha, Saudi Arabia

Abstract

Background: Minimally invasive oculoplastic surgery (MIOS) aims to reduce scarring, tissue trauma, morbidity, and recovery time while preserving periocular function and cosmesis. Our systematic review synthesized techniques and outcomes in selected MIOS. **Methods:** A PRISMA-based systematic review was conducted using PubMed, Scopus, Web of Science, and Embase. Original studies evaluating MIOS with postoperative outcome data were included. Data on study characteristics, procedures, populations, follow-up, and outcomes were extracted and synthesized qualitatively because of heterogeneity. **Results:** Six eligible original studies were included, covering transconjunctival (TC) lower eyelid blepharoplasty, TC orbitotomy for intraconal orbital hydatid cysts, and endoscopic dacryocystorhinostomy (DCR). TC blepharoplasty showed good recovery, scar-free access, and low rates of major complications, with most short-term symptoms resolving within 1 to 2 weeks. TC orbitotomy had successful cyst removal in all reported cases, with early symptom improvement and no recurrence during follow-up. In endoscopic DCR studies, success rates were high, silicone tubing did not show significant benefit in primary cases, Kerrison punch (K-punch) shortened operative time compared with powered drill, and the double-flap technique reduced recurrence compared with the single-flap technique. **Conclusion:** MIOS showed good effectiveness and safety in selected indications, and the data remained limited by small study numbers, retrospective designs, and heterogeneity.

Keywords: Minimally invasive oculoplastic surgery; oculoplastic surgery; transconjunctival blepharoplasty; transconjunctival orbitotomy; endoscopic dacryocystorhinostomy; surgical outcomes

Published: May 3, 2026

<https://doi.org/10.65759/8393we78>

Copyright © 2025 The Author(s). Published by Lizzy B. This is an open-access article distributed under the terms of the Creative Commons Attribution (CC BY 4.0) license, which permits unrestricted use, distribution, and reproduction in any medium, provided the original work is properly cited).

Introduction

Minimally invasive oculoplastic surgery (MIOS) is an important direction in oculoplastic practice and it aims to reduce visible scarring, tissue trauma, operative morbidity, and recovery time while preserving function and periocular cosmesis in eyelid, lacrimal, and orbital procedures (Naik 2009; Bhattacharjee 2020; Liu 2024; Tong 2026). This shift has been driven by periocular region contribution to facial aging and quality of life, and that successful surgery in this area depends on correcting pathology, and preserving lid position, ocular surface integrity, tear function, and a natural lid-cheek relationship through careful patient selection and meticulous preoperative assessment (Naik 2009; Bhattacharjee 2020).

In lower eyelid surgery, literature shows a evolution from subtractive surgery toward tissue-preserving strategies that emphasize conservative fat handling, fat transposition, and restoration of smooth contour rather than aggressive excision alone, especially in patients with steatoblepharon and tear trough deformity (Bhattacharjee 2020; Naik 2009). Within this context, the transconjunctival (TC) approach has gained importance because it is preferred in younger patients with orbital fat herniation and limited skin redundancy, and it has been associated with less postoperative scarring, lower risk of ectropion and scleral show, and a favorable scarless route to the lower fat pads when compared with traditional transcutaneous access in selected cases (Bhattacharjee 2020; Naik 2009).

Minimally invasive internal access affected other eyelid procedures, as TC posterior-approach ptosis surgery has evolved from historical Müller muscle and conjunctival resection techniques to white-line advancement methods that used in aponeurotic

ptosis patients with moderate to good levator function (Patel 2010). Dacryocystorhinostomy (DCR) is the cornerstone for distal nasolacrimal duct obstruction. Endoscopic approaches have gained popularity because it avoids external scars, shorten recovery, and address intranasal pathology (Jawaheer 2017; Panda 2023; Liu 2024; Locatello 2024).

The uncertainty regarding the performance of external and endoscopic lacrimal procedures is important, since the Cochrane review found low-certainty evidence and show that differences in outcome depend on the specific endonasal technique, whereas newer meta-analyses indicate that endoscopic procedures offer advantages in bleeding, hospital stay, OT, or adverse events (Jawaheer 2017; Panda 2023; Liu 2024; Locatello 2024). In this systematic review we aimed to analyze original clinical studies on current MIOS and their reported outcomes in TC lower eyelid blepharoplasty, TC orbitotomy, and endoscopic DCR.

Methods

This systematic review was conducted to evaluate current MIOS and their clinical outcomes. The review process was structured according to the Preferred Reporting Items for Systematic Reviews and Meta-Analyses (PRISMA) framework. Electronic database searching was performed in PubMed, Scopus, Web of Science, and Embase. The search strategy combined controlled terms and free-text keywords related to MIOS, including terms “minimally invasive,” “oculoplastic,” “transconjunctival,” “endoscopic,” “blepharoplasty,” “dacryocystorhinostomy,”

“orbitotomy,” “technique,” and “outcome.” The retrieved records from all databases were exported and screened after removal of duplicates.

Original clinical studies were considered eligible if evaluated a MIOS technique and reported postoperative outcomes, recovery, recurrence, complications, or procedural success. Eligible designs included prospective studies, retrospective studies, comparative studies, cohort studies, case series, and randomized trials. Studies were excluded if they were review articles, editorials, conference abstracts, animal studies, purely anatomical or cadaveric reports, technical notes without patient outcomes, or studies not directly focused on MIOS. Articles that did not provide sufficient outcome data or were not relevant to the review topic were excluded.

Study selection was performed in two stages. First, titles and abstracts were screened to identify relevant studies. Second, full texts of the selected articles were reviewed for final eligibility. The screening process was based on relevance to the review question, originality of the study design, and the presence of extractable clinical outcome data. The reasons for exclusion at the full-text stage included lack of direct relevance to MIOS, absence of postoperative outcomes, or failure to meet the predefined inclusion criteria. The overall study selection process was summarized using a PRISMA flow diagram (Fig 1).

Data were extracted from the included studies using a standardized approach. The extracted variables included first author, year of publication, country, study design, type of MIOS, study population or indication, sample size, duration of follow-up, and the main postoperative findings and outcomes. Attention was given to outcomes reflecting

effectiveness and safety, symptom improvement, anatomical success, recurrence, complication profile, recovery time, and need for additional procedures. These extracted data were organized into summary tables describing the characteristics of the included studies and their main findings.

Because the included studies were heterogeneous in terms of surgical indications, procedural techniques, study design, and reported outcome measures, a quantitative meta-analysis was not appropriate. The findings were synthesized qualitatively. The included studies were grouped according to the main procedural category, including TC lower eyelid blepharoplasty, TC orbitotomy, and endoscopic DCR. This approach allowed comparison of the current techniques and their reported outcomes in different MIOS.

Results

Six eligible original studies were included in this review. The included articles examined MIOS in three main domains, TC lower eyelid blepharoplasty, TC orbitotomy for intraconal orbital lesions, and endoscopic DCR for nasolacrimal duct obstruction. Study designs included retrospective case series, retrospective comparative studies, a quasi-experimental comparative study, and one prospective randomized trial. Sample sizes ranged from 5 to 173 cases, showing that the available data was heterogeneous in design and scale.

Two studies evaluated TC lower blepharoplasty. In the earlier series by Korchia et al., twenty-three patients underwent retro-septal TC lower blepharoplasty, for palpebral lipo-ptosis without skin excess. The authors reported good access to the inferior fat compartments, a scar-free approach,

and a lower complication profile than the classic transcutaneous technique, with no case of postoperative lid retraction. In the larger study by Gupta et al., eighty-eight patients underwent TC post-septal blepharoplasty. The median age was 48 years, and ancillary procedures were combined with the main approach, including excess skin excision in 31 patients, canthoplasty or canthopexy in 19 patients, and fat transfer in 87 patients. Mean operative time (OT) was 8 minutes 47 seconds for isolated lower TC blepharoplasty and increased when combined with adjunctive procedures.

Regarding postoperative outcomes after TC blepharoplasty, the Gupta study, swelling, bruising, and chemosis were common after surgery but mostly resolved within 1 to 2 weeks. Foreign body sensation occurred in 14 patients and resolved within 48 to 72 hours. Symptomatic dry eye decreased over follow-up and was absent by 12 weeks. Return to social activity occurred within 2 weeks in most patients, while no hemorrhage, visual problems, inferior oblique injury, corneal trauma, long-term lid retraction, or persistent dry eye were reported. Korchia et al. show scar-free results and low complication rates.

One study addressed TC anterior orbitotomy for intraconal orbital hydatid cysts. Awad and Mohammad included 5 patients aged 11 to 44 years. All lesions were excised successfully after aspiration and collapse of the cyst through a TC approach. Proptosis improved within 2 weeks in all patients, visual acuity improved in four cases, and disc edema, pain, and limited motility resolved within 1 month. One transient conjunctival prolapse was reported, and no permanent complications or recurrence were observed during follow-up of 11 to 58 months. Characteristics of the included studies

and main findings presented in Table 1 and 2 respectively.

Three studies evaluated endoscopic DCR. Herzallah et al. reported 66 DCR procedures in 59 patients and found comparable success between powered drill and kerrison punch (K-punch) techniques, with success rates of 90.91% and 87.88%, respectively, but a shorter OT with the K-punch. Minor complications occurred in 18%, with no major complications. In the randomized study by Al-Qahtani, 173 patients underwent primary endoscopic DCR with or without silicone tubing. Success was 96.7% with silicone tubing and 90.1% without tubing, but the difference was not significant. In the study by Bani-Ata et al., 77 cases were analyzed, and recurrence was lower with the double-flap technique than with the single-flap technique (3.2% vs 23.9%).

Fig 1: PRISMA flow chart

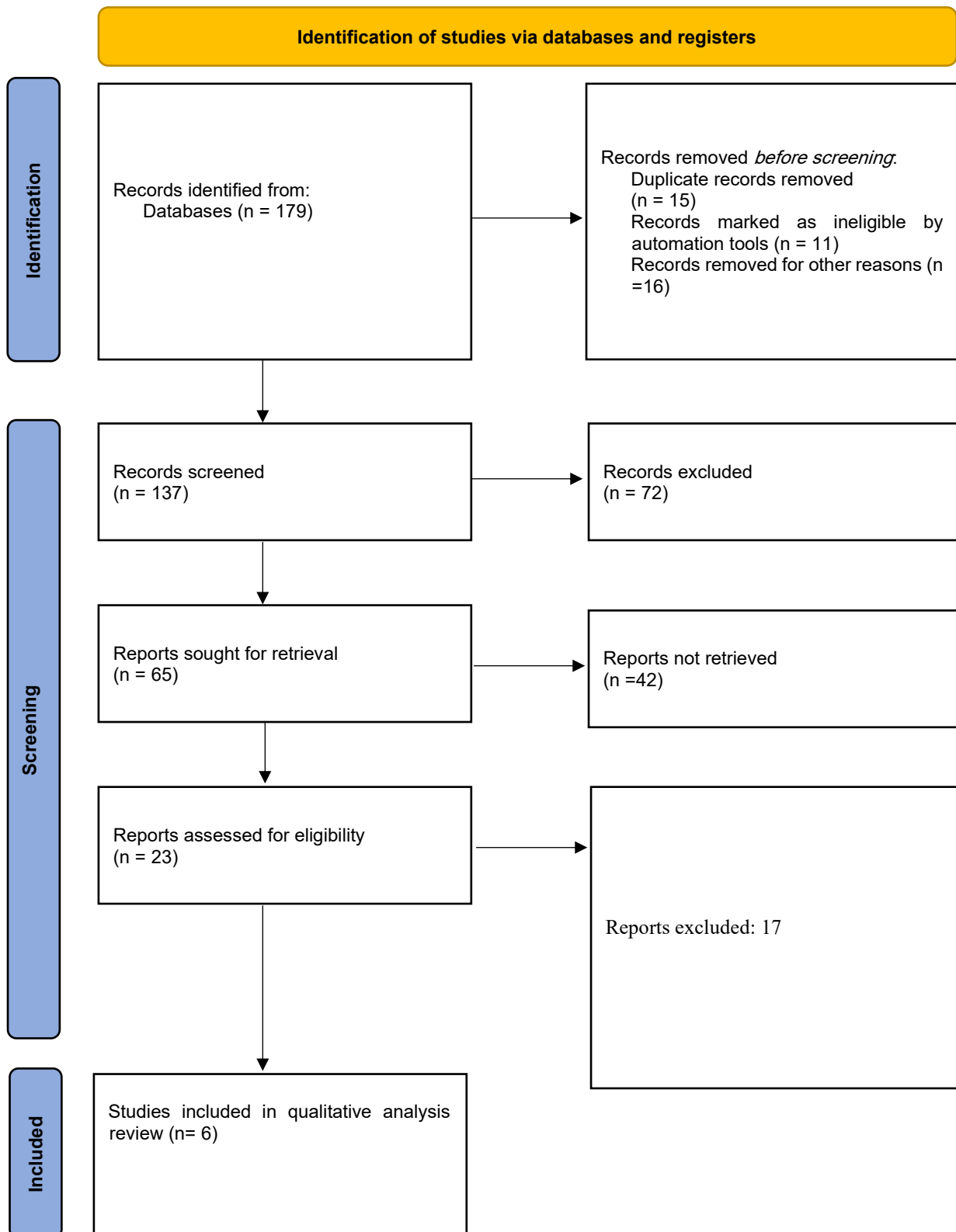


Table 1. Characteristics of the included studies

Study	Country	Study design	MIOS	Population and indication	Sample size	Follow-up
Herzallah et al., 2015	Saudi Arabia	Retrospective chart review	Endoscopic DCR (powered drill vs K-punch)	Nasolacrimal duct obstruction / epiphora	66	Mean 8.2 months
Al-Qahtani, 2012	Saudi Arabia	Prospective randomized study	Primary endoscopic DCR with vs without silicone tubing	Saccal/postsaccal stenosis or nasolacrimal duct obstruction	173	12–15 months
Bani-Ata et al., 2020	Jordan	Retrospective quasi-experimental comparative study	Endoscopic DCR using single-flap vs double-flap mucosal techniques	Primary nasolacrimal duct obstruction	77	At least 1 year; mean follow-up about 21.6 months overall
Korchia et al., 2003	France	Case series	TC lower eyelid blepharoplasty (retroseptal approach)	Esthetic lower eyelid fat prolapse / palpebral lipoptosis	23	3 months
Gupta et al., 2024	India	Retrospective observational single-center study	TC postseptal blepharoplasty	Lower eyelid bags; some cases combined with skin excision, canthopexy/canthoplasty, or fat transfer	88	12 weeks
Awad & Mohammad, 2025	Egypt	Retrospective non-comparative clinical intervention case study	TC anterior orbitotomy with cyst aspiration and removal	Intraconal orbital hydatid cyst	5	11–58 months (mean 25 months)

Table 2. Main findings and outcomes of the included studies

Study	Main findings and outcomes
Korchia et al., 2003	The TC lower blepharoplasty approach was scar-free, provided excellent access to lower eyelid fat, and had lower complications than the classic transcutaneous approach. Mean bilateral OT was 40 minutes. Reported postoperative effects included moderate edema in 5 patients, ecchymosis in 2, one transient red eye/allergic reaction, and 2 undercorrections of residual bags; no round eye/ectropion was reported.
Gupta et al., 2024	In 88 patients, postoperative swelling, bruising, and chemosis usually resolved within 1–2 weeks; foreign-body sensation occurred in 14 patients (15.73%) and resolved within 48–72 hours. Return to social life was 1 week in 22%, 2 weeks in 67%, 3 weeks in 9%, and 4 weeks in 2%. There were no hemorrhage, visual problems, inferior oblique injury, corneal trauma, lid retraction, or long-term dry eye. OT was 8 min 47 s for isolated TC blepharoplasty and increased with adjunctive procedures.

Study	Main findings and outcomes
Awad & Mohammad, 2025	All 5 intraconal hydatid cyst cases were managed successfully by TC orbitotomy after cyst aspiration and collapse. The approach allowed safe localization, aspiration, and one-piece removal of the endocyst. During follow-up, no recurrence was reported.
Herzallah et al., 2015	In 66 endoscopic DCRs, success was 90.91% with powered drill vs 87.88% with K-punch, with no significant difference in success or complications. Mean OT was significantly shorter with K-punch (75 min) than drill (125 min, $p=0.0001$). Minor complications were 18% including intranasal synechiae, stent fall-out, eye/cheek bruising, and nostril burn; no major complications were reported.
Al-Qahtani, 2012	In 173 randomized endoscopic DCR cases, success was 96% with silicone tubing and 91% without tubing, for an overall success of 94%; the difference was not statistically significant ($p=0.117$). Mean OT was 35 min with stent vs 23 min without stent. The study concluded there was no significant advantage to silicone stenting in primary endoscopic DCR.
Bani-Ata et al., 2020	Among 77 endoscopic DCR cases, recurrence occurred in 23.9% of the single-flap group versus 3.2% of the double-flap group ($p=0.022$). The authors concluded that the double-flap technique reduced recurrence, by covering exposed lacrimal bone and reducing postoperative adhesions over the ostium.

Discussion

This review analyzed six original studies which found that MIOS is applied in three distinct clinical settings, TC lower eyelid blepharoplasty, TC orbitotomy, and endoscopic DCR, with favorable effectiveness and safety profiles. The lower blepharoplasty studies in this review supported the value of the TC route, as Korchia reported scar-free access and no round eye or ectropion, while Gupta described predominantly self-limited postoperative swelling, bruising, chemosis, and foreign-body sensation with return to social life within a few weeks and no long-term lid retraction, persistent dry eye, visual problems, or corneal trauma, which is consistent with broader review literature favoring the TC approach in suitable patients because of less visible scarring and lower rates of scleral show and ectropion compared with transcutaneous techniques (Bhattacharjee 2020; Naik 2009).

The present study findings should not be interpreted as showing that TC surgery is universally better for all lower lid cases, because the attached reviews stress that patient selection is decisive and transcutaneous approaches are needed when additional skin-muscle management is required, which helps explain why modern lower blepharoplasty is best viewed as a tailored (Bhattacharjee 2020; Naik 2009). The single included study on TC anterior orbitotomy indicate that minimally invasive internal access can be effective beyond cosmetic eyelid surgery, since Awad and Mohammad achieved complete excision of intraconal hydatid cysts with early improvement in proptosis and other symptoms, only one transient conjunctival prolapse, and no recurrence during follow-up, while the broader transorbital neuroendoscopic literature describes the orbit as a useful minimally invasive corridor that provide

direct access, favorable visualization, and reduced morbidity for selected orbital and cranio-orbital lesions (Tong 2026).

Among the procedure groups in this review, the data was most developed for endoscopic DCR, where Herzallah found similar success and complication rates between powered drill and K-punch techniques but a shorter OT with the K-punch, Al-Qahtani found no significant advantage for silicone intubation in primary endoscopic DCR, and Bani-Ata showed lower recurrence with the double-flap technique than with the single-flap technique (Bani-Ata 2020). These findings agree in part with the attached secondary literature, which describes endoscopic DCR as a current workhorse procedure with satisfactory outcomes but ongoing uncertainty about the optimal operative method, perioperative adjuncts, and the real value of several technical modifications because much of the literature is methodologically heterogeneous (Locatello 2024).

Comparison with the meta-analytic literature shows that conclusions depend heavily on which endoscopic technique is evaluated, because Panda et al. 2023 found that endoscopic laser DCR was associated with less bleeding, less infection, and shorter OT than external DCR but lower overall success, Liu et al. reported similar surgical success with better perioperative outcomes and fewer adverse events for endoscopic DCR in dacryocystitis, and the Cochrane review by Jawaheer concluded that the relative effects of endonasal and external DCR is uncertain because the available randomized evidence was very low certainty and technique-specific differences were important (Panda 2023; Liu 2024; Jawaheer 2017). The current review supports the idea that the main strength of MIOS

lies in its ability to achieve outcomes with less visible scarring, faster recovery, and limited morbidity in carefully selected patients (Locatello 2024; Bhattacharjee 2020).

The main limitations of our review are the small number of eligible studies, predominance of retrospective designs, small sample size in the orbitotomy evidence, and heterogeneity in indications and outcome reporting. Future research should prioritize better prospective comparative studies with standardized anatomical and functional outcomes, longer follow-up, and clearer stratification by technique in order to define where MIOS offers true clinical advantage rather than cosmetic appeal.

Conclusion

MIOS has promising clinical value in selected eyelid, orbital, and lacrimal procedures. TC blepharoplasty provided scar-free access with favorable recovery and low major complication rates, TC orbitotomy achieved successful removal of intraconal hydatid cysts with good cosmetic and clinical outcomes, and endoscopic DCR show high success with technique-related differences in OT and recurrence. Larger prospective comparative studies with standardized outcomes and longer follow-up are needed to strengthen conclusions in future research settings.

List of abbreviations

DCR, Dacryocystorhinostomy; Fig, Figure; K-punch, Kerrison punch; min, minutes; MIOS, minimally invasive oculoplastic surgery; n, number; OT, operative time; p, p-value; PRISMA, Preferred Reporting Items for Systematic Reviews and Meta-

Analyses; s, seconds; TC, transconjunctival; vs, versus.

References

- Al-Qahtani AS. Primary endoscopic dacryocystorhinostomy with or without silicone tubing: A prospective randomized study. *Am J Rhinol Allergy*. 2012;26(4):332-4. doi: 10.2500/ajra.2012.26.3770.
- Awad AA, Mohammad AEN. A simple transconjunctival technique for the management of intraconal orbital hydatid cyst. *Indian J Ophthalmol*. 2025;73(2):249-252. doi: 10.4103/IJO.IJO_756_24.
- Bani-Ata M, Aleshawi A, Ahmad M, Saleh O, Ashour R, Khalil H, Alomari S, Alhowary AA. Endoscopic dacryocystorhinostomy: A comparison of double-flap and single-flap techniques. *Ann Med Surg (Lond)*. 2020;54:1-5. doi: 10.1016/j.amsu.2020.03.003.
- Bhattacharjee K, Ghosh S, Ugradar S, Azhdam AM. Lower eyelid blepharoplasty: an overview. *Indian J Ophthalmol*. 2020 Oct;68(10):2075-2083. doi: 10.4103/ijo.IJO_1291_20.
- Eldsoky I, Ismaiel WF, Hasan A, Abdelazim MH, Ibrahim AA, Alsobky ME, Mohammed AR. The predictive value of nasolacrimal sac biopsy in endoscopic dacryocystorhinostomy. *Ann Med Surg (Lond)*. 2021;65:102317. doi: 10.1016/j.amsu.2021.102317.
- Gupta R, Khosa A, Bansal P, Chaudhury G. Exploring the Versatility of Transconjunctival Blepharoplasty: A Retrospective Single-Center Study. *Cureus*. 2024;16(11):e72929. doi: 10.7759/cureus.72929.
- Herzallah I, Alzuraiqi B, Bawazeer N, Marglani O, Alherabi A, Mohamed SK, Al-Qahtani K, Al-Khatib T, Alghamdi A. Endoscopic Dacryocystorhinostomy (DCR): a comparative study between powered and non-powered technique. *J Otolaryngol Head Neck Surg*. 2015;44(1):56. doi: 10.1186/s40463-015-0109-z.
- Jawaheer L, MacEwen CJ, Anijeet D. Endonasal versus external dacryocystorhinostomy for nasolacrimal duct obstruction. *Cochrane Database Syst Rev*. 2017 Feb 24;2(2):CD007097. doi: 10.1002/14651858.CD007097.pub3.
- Korchia D, Braccini F, Paris J, Thomassin JM. Transconjunctival approach in lower eyelid blepharoplasty. *Can J Plast Surg*. 2003;11(3):166-70.
- Kotb AN, Salamah MA, Khalil AS, Dessouky RAK. Outcomes of a novel algorithm for levator muscle plication surgery in congenital blepharoptosis. *BMC Ophthalmol*. 2024;24(1):22. doi: 10.1186/s12886-024-03287-y.
- Liu S, Zhang H, Zhang YR, Chen LJ, Yu XY. The efficacy of endoscopic dacryocystorhinostomy in the treatment of dacryocystitis: A systematic review and meta-analysis. *Medicine (Baltimore)*. 2024;103(13):e37312. doi: 10.1097/MD.00000000000037312.
- Locatello LG, Redolfi De Zan E, Caiazza N, Tarantini A, Lanzetta P, Miani C. A critical update on endoscopic dacryocystorhinostomy. *Acta Otorhinolaryngol Ital*. 2024 Oct;44(5):351-360. doi: 10.14639/0392-100X-N2916.
- Naik MN, Honavar SG, Das S, Desai S, Sendhilnathan S. Blepharoplasty: an overview. *J Cutan Aesthet Surg*. 2009 Jan;2(1):6-11. doi: 10.4103/0974-2077.53092.
- Panda BB, Nayak B, Mohapatra S, Thakur S, Vishwanath S. Success and complications of endoscopic laser dacryocystorhinostomy vs. external dacryocystorhinostomy: A systematic review and meta-analysis. *Indian J Ophthalmol*. 2023;71(10):3290-3298. doi: 10.4103/IJO.IJO_3334_22.
- Patel V, Malhotra R. Transconjunctival blepharoptosis surgery: a review of posterior approach ptosis surgery and posterior approach white-line advancement. *Open Ophthalmol J*. 2010;4:81-84. doi: 10.2174/1874364101004010081.
- Tong JY, Sung J, Machado de Andrade W, Chan WO, Psaltis AJ, Selva D. An oculoplastic perspective on transorbital neuroendoscopic surgery: anatomical corridors and clinical applications. *Taiwan J Ophthalmol*. 2026;16(1):26-34. doi: 10.4103/tjo.TJO-D-25-00171.